

# Septic arthritis



# Paths of infection

## ▶ Blood stream –

- children particularly prematures and those with septicaemia
- adults particularly with immune def. pre-existing disease

## ▶ Direct spread-

- from bone
- hip from pelvic organs

# Sequelae

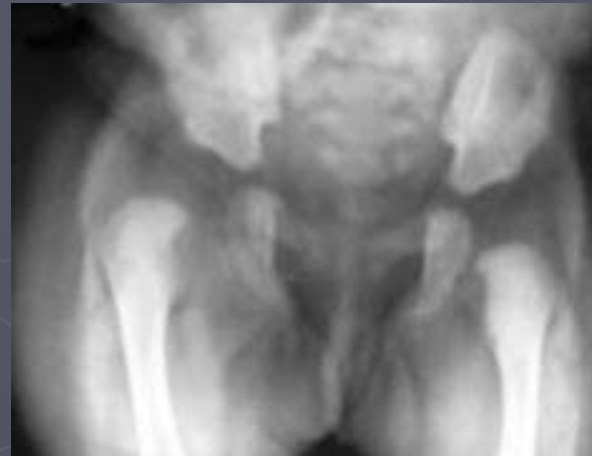
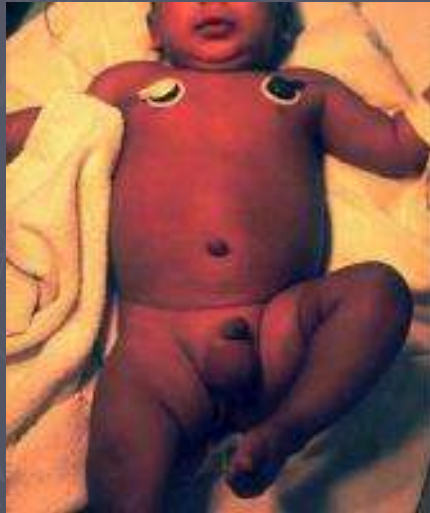- ▶ Subluxation, dislocation
  - ▶ Variable degree of loss of articular cartilage
  - ▶ Fibrous ankylosis
  - ▶ Epiphysis maybe destroyed (infection, AVN)
- Tom Smith Arthropathy

# Diagnosis



# Diagnosis

- ▶ History
- ▶ Warm, swollen, red, tender
- ▶ NO movement
- ▶ Neonates – flexed. Pseudo-paralysis



# Investigations

- ▶ ESR, CRP, WBCC
- ▶ Blood culture
- ▶ Aspiration

# Treatment



# Treatment

- ▶ Adequate, early drainage
- ▶ Aspiration is NOT a treatment
- ▶ Arthrotomy or arthroscopy
- ▶ Antibiotics

# Approach

- ▶ Hip – inferior limb of the Smith-Petersen
- ▶ Shoulder – anterior
- ▶ Elbow – lateral
- ▶ Knee - lateral

# Painful hip in a child

- ▶ Perthes
- ▶ SUFE
- ▶ Transient synovitis
  
- ▶ Septic arthritis